



long-term stability with ankylos

A challenge every time – immediate implant placement and restoration on the front line

| Patric Renner

INTRODUCTION

In the context of civilian life, being on the front line means being right out in front and therefore exposed to public view. Owing to their position, front teeth have a significant influence on the visual impression a face makes. In this respect, this is a sensitive area for patients. The patient places high demands on the dentist with regard to all corrections in this region.

There should be no difference apparent between the red-white esthetics of the implant-supported dental prosthetics and natural dentition. Several factors have to coincide in order to provide the patient with the legitimate hope for the desired result. Besides the relevant patient health and anatomical conditions, the implant system plays a crucial role.

The implant's macro design and the intraoperative protocol form the basis for success. They help prevent undesired bone loss and the consequent recession of soft tissue. This assumes the patient works towards the same goals. In the case of single tooth replacement, the therapy goal set can be best achieved with immediate implant placement as atraumatic as possible

and prompt temporary restoration. It is of considerable benefit if a permanent ceramic abutment is used 'one abutment one time' at this point in time.

Most restorations look good after integration. But what will it look like after a couple of years? The goal of therapy can only be considered as achieved once the initial result has remained stable for an extended period of time. This cannot be achieved without durably preserving hard and soft tissue. Support for the soft tissue, as well as functional aspects, can be taken into consideration as early as the planning phase. A garland-shaped, scar-free gingiva line, attractive interdental papillae and sufficient keratinized gingiva are important parameters for esthetics. However, these parameters are significantly influenced by the implant design and the vertical positioning of the implant shoulder. The material properties and the constructional elements of the abutment components are also of importance. Additional factors are optimal function and, above all, material-induced longevity and biocompatibility of the restoration.

**TISSUECARE: RELIABILITY OF A CONCEPT**

Whether the desired esthetic result is achieved also depends on the extent to which the “biological width” can be established and stabilized as immune-competent tissue at the site of emergence of the implant. A bacteria-proof implant-abutment interface that has been displaced horizontally due to platform-switching, as offered by the Ankylos implant, provides favorable conditions in this case. The gap-free, friction-locked and keyed taper connection between the implant and abutment remains free of bacterial colonization. Apical migration of the epithelial tissue and decay of peri-implant bone is prevented. Under these conditions, the implant can also be inserted subcrestally. As a result of the microstructured implant shoulder, the bone grows over the implant shoulder onto the interface to the abutment. Preserving the interdental septum lays the foundations for long-term osseous support for the gingiva and a natural emergence profile.

IMMEDIATE IMPLANT PLACEMENT AND IMMEDIATE RESTORATION: THE PROS OUTWEIGH THE CONS

Immediate implant placement – with a root-shaped implant body and a corresponding parallel-walled compression thread – offers advantages, especially considering soft tissue esthetics. If extraction and implant insertion immediately thereafter are as atraumatic and tissue-conserving as possible, the alveolar process is preserved. The commonly occurring loss of hard and soft tissue structures can be avoided. Also, duration and stress of treatment is reduced for the patient. Immediate support for the soft tissue architecture is achieved if the permanent abutment is screwed in and provided with a temporary crown as quickly as possible. The outcome is similar to a transgingivally placed, single-component implant, only possessing all the advantages of flexible prosthetic restoration of a two-component implant.

CASE AND TREATMENT PLANNING

In August 2004, a 43-year-old patient presented herself in the practice for the first time. She complained of mild symptoms in region 12. The gingival margin was slightly reddened and the tooth was sensitive to percussion and bite (Fig. 1). The retainers had been placed 16 years previously as part of orthodontic treatment. Tooth 12 had been treated alio loco with a cast pin and a metal-ceramic crown (Fig. 2). The pin together with the crown had already loosened twice and had been refastened. There were no functional complaints, preexisting disease or allergies; the periodontal status was inconspicuous. The X-ray showed a somewhat incomplete root filling on tooth 12 (Fig. 3). There was slight apical translucency. There was also the suspicion of a hair-line fracture in the root. Tooth 12 was no longer considered worthy of preservation. The patient was informed in detail of the possibilities of restoration. She decided for the implantological procedure for esthetic reasons, the prospect of a short treatment period but also as a way of preserving the substance of the adjacent teeth. The goal was immediate restoration with a temporary crown on a permanent

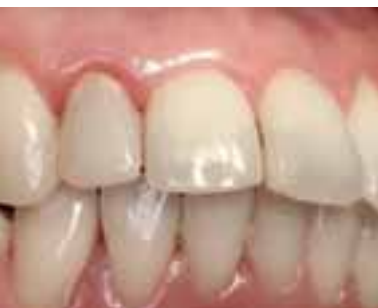abutment. She was prepared to be “toothless” for a day for this opportunity. A full ceramic crown was intended as the final restoration.

PREOPERATIVE: PROVISIONAL SOLUTION AND DRILLING TEMPLATE

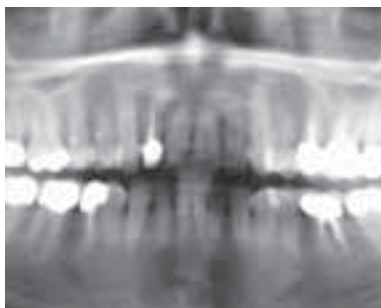
For the provisional restoration, tooth 12 was removed preoperatively from the situation model and a wax-up was produced in the esthetically correct position within the dental arch (Fig. 4). The situation was held with a front and back wall and a drilling template was produced as a positioning aid for accurate insertion (Fig. 5). The reduced silicone key provided the model for the anatomically-oriented shape of the permanent abutment to facilitate fabrication of a temporary plastic solution.

ATRAUMATICALLY EXTRACTED AND FUNCTIONALLY-ESTHETICALLY INSERTED

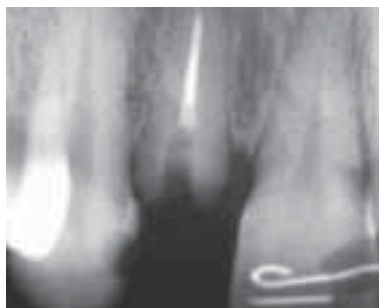The procedure took place under local sedation in December 2004. The largely atraumatic extraction using a periosteal elevator conserves the labial bone lamella. Once the extraction alveoli



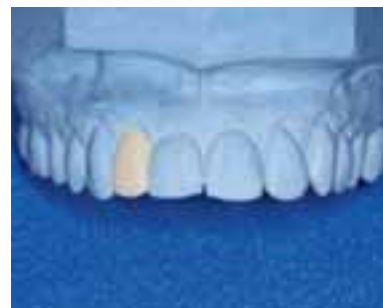1_



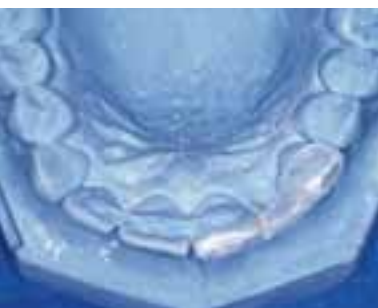2_



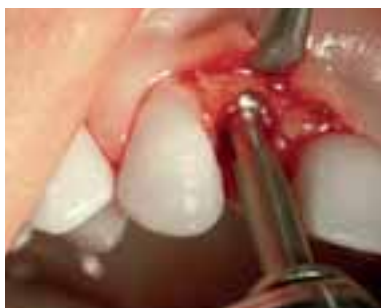3_



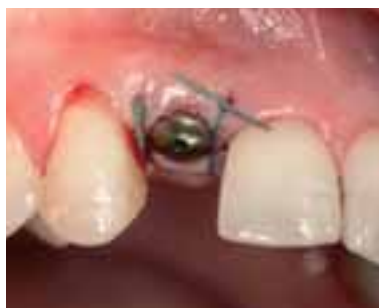4_



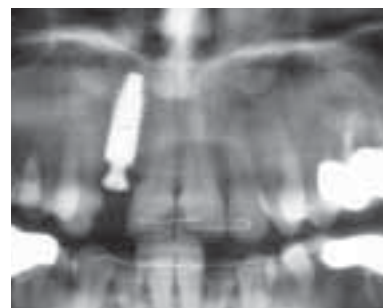
5_



6_



7_



8_

were carefully cleaned apically of granulation tissue, the implant site was conditioned slightly palatally according to protocol (Fig. 6). The Ankylos implant (B 14) was inserted slightly subcrestally. This meant that the existing mucosa thickness was not unnecessarily reduced. The implant diameter was selected such that the 2 mm mesio-distal distance to the adjacent teeth could be maintained. Ankylos with its progressive, condensing thread design compacted the bone thus achieving the required primary stability. Augmentative measures were not required, as the jumping distance was below 1 mm. An Ankylos sulcus former was screwed in immediately after insertion to prevent the collapse of the soft tissue (Fig. 7). The exact position of the implant was verified with a postoperative X-ray (Fig. 8).

The crestal situation allowed the immediate temporary restoration as planned. After suturing, the sulcus former was therefore removed again and a transfer post was inserted (Fig. 9). An impression was taken with an individual open tray. The sulcus former was then reinserted. The patient left the practice this day without a provisional restoration.

PERMANENT ABUTMENT AND TEMPORARY RESTORATION

The individualized full ceramic abutment (Ankylos Cercon Balance, small) was available the next day from the dental technician (Fig. 10). The sulcus former and suture were removed. A transfer key was also supplied allowing the precise positioning of the abutment, its tapered connection geometry allowing it to be positioned freely. It was possible to insert the permanent abutment one day after implant placement. Since no temporary abutment has to be removed with this 'one abutment one time' method, possible irritation of the gingiva is avoided from the outset.

The plastic temporary restoration produced preoperatively in the dental laboratory was fixed onto the abutment with temporary plastic cement (Fig. 11). The provisional crown has no occlusal contact either statically or dynamically allowing unproblematic healing of the implant. The approximal contacts were also purposefully eliminated. The perio-test value ("Tübinger Specht") was -2. The patient was instructed to be gentle on the anterior region and not to bite with force.

1, 2_The initial situation

3_Individual X-ray of tooth 12 shows the defective root filling and a slight apical translucency with a suspected chronic apical osteitis.

4_The situation model with wax-up

5_The positioning aid

6_Conservative preparation of the implant site

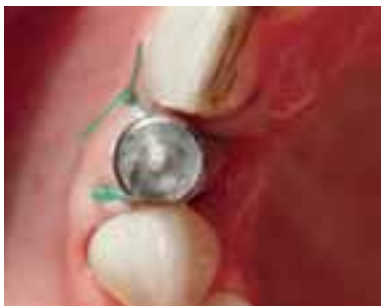7_Soft tissue adapted to the sulcus former using a single interrupted suture

8_Situation immediately after insertion

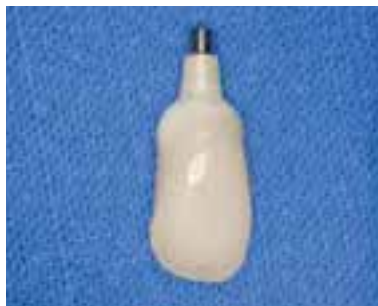9_The orientation of the implant is identifiable from the transfer post.

10_The temporary crown on the individualized, permanent zirconia abutment (Ankylos Cercon Balance)

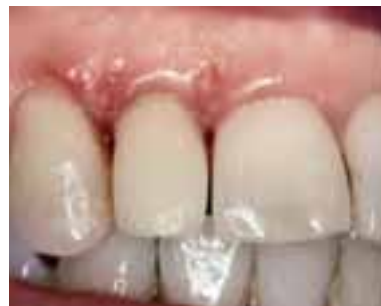11_The temporary restoration one day after integration. The sutures have already been removed.



9_



10_



11_

FIVE MONTHS LATER

Time is an important factor for functional and esthetic success. Oral tissue needs sufficient time to regenerate and stabilize. An anatomical design of the temporary restoration not only supports the soft tissue structures. In combination with the similarly anatomically shaped permanent abutment, a bacteria-proof seal can be formed, comparable with the dento-gingival seal. After three months, the tissue is irritation-free and the implant has healed stably (Figs. 12 and 13). Extremely hard yttrium-stabilized (Y_2O_3) zirconia (ZrO_2) is used for the full ceramic Cercon abutments. This high performance ceramic is not only characterized by its very high strength, but also by outstanding esthetics and biocompatibility. Its low plaque absorption reduces the risk of soft tissue recession.

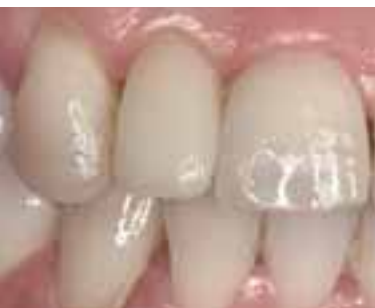The permanent dental restoration was fabricated and integrated in May 2005. First, the full ceramic cap, prefabricated with the temporary crown on the original abutment, was temporarily fixed onto the Cercon abutment with Temp Bond Nogenol

(Figs. 14 to 16). A pick-up impression was then taken with Impregum (Fig. 17). A full ceramic crown made of leucite-reinforced glass ceramic produced with the press-over technique was then inserted with adhesive on June 6, 2005. (Fig. 18 and 19) The perio-test value was -4. The X-ray control showed no abnormalities (Fig. 20).

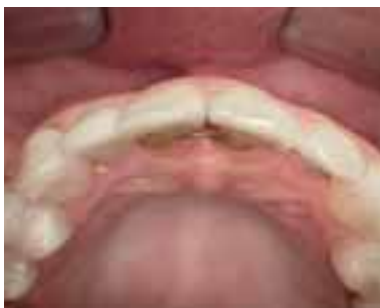YEARS LATER ...

At a follow-up examination a year later (Fig. 21) the perio-test value was -3. The digital X-ray taken on this occasion showed stable peri-implant bone conditions (Fig. 22). The yearly follow-up examinations showed no negative changes in the restoration and the surrounding tissue (Fig. 23).

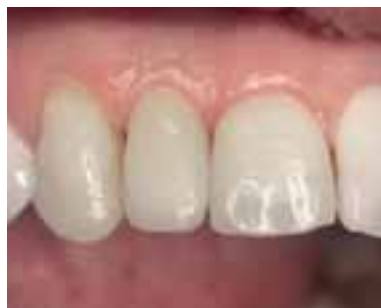The X-ray taken in December 2009, i.e. five years after implant placement, impressively documents the stable bone conditions (Fig. 24). The basic requirements for esthetic success in front teeth restoration – a garland-shaped gingival line and full interdental papillae – are thus fulfilled.



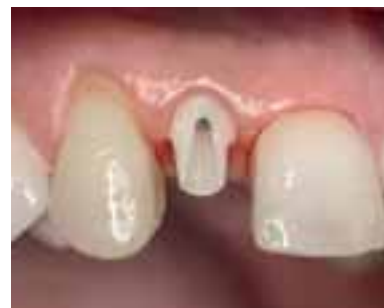12_



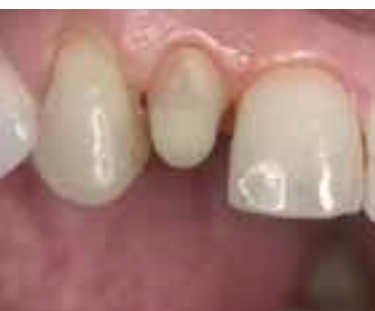13_



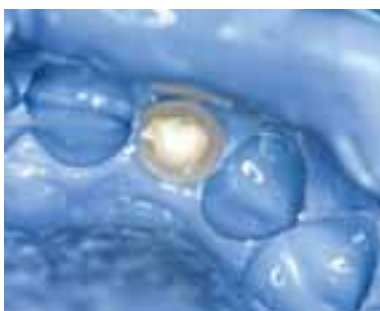14_



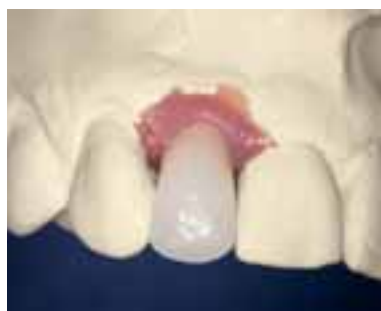15_



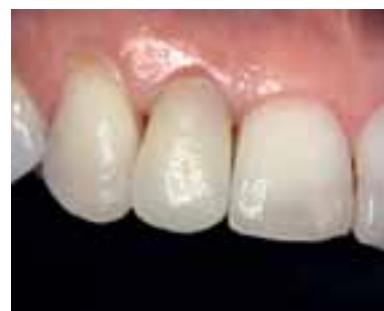16_



17_



18_



19_

CLOSING OBSERVATIONS

Immediate restoration following immediate implant placement with an implant-supported single tooth crown in the esthetically sensitive anterior region may be termed state-of-the-art. This assumes that the decisive criteria, such as patient selection and suitability of the implant system and its components, are taken into consideration. In addition, the physician should have a sound knowledge of peri-implant structures and possible changes in them. The primary stability of the implant and the infraocclusion of the temporary crown are further parameters for success, alongside patient compliance. If these factors are considered, predictable, functional, stable and esthetic long-term results can be achieved. ■



Dr Patric Renner
 Specialist for oral surgery
 Hauptstr. 48
 63773 Goldbach /Germany
 Phone +49 6021 51684
 www.renner-brueckner.de
 Specialization in implantology (BDIZ)
 Specialization in esthetic dentistry (DGÄZ)
 Specialist for implantology (EDA)

12, 13_The gingiva is irritation-free and stable at the follow-up examination after three months.

14_The clinical situation after five months prior to fabrication of the permanent crown

15_Situation after removal of the temporary restoration

16_The full ceramic cap was manufactured months earlier together with the individualized abutment. It is temporarily fastened for impression taking.

17_Impression taking (Impregum) with the cap

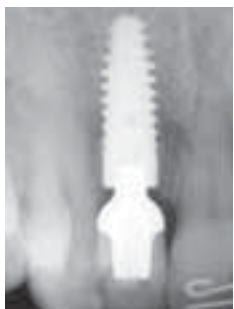18, 19_The ceramic crown on the master model and in the mouth

20_The control image of the permanent restoration clearly shows the excellent bone apposition. The perio-test value was -4.

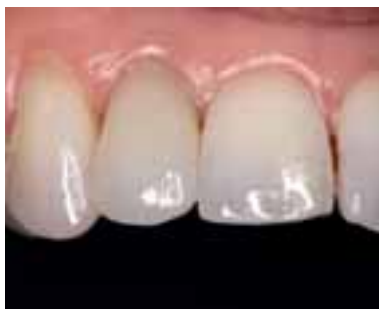21_The situation after almost a year (March 2006)

22_Clinical situation another year later (February 2007)

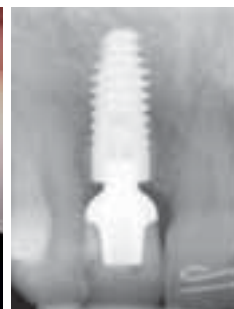23_Still no recession identifiable on the peri-implant bone five years after insertion.



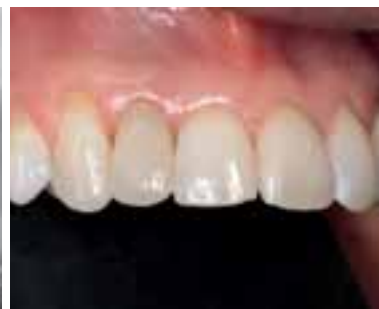20_



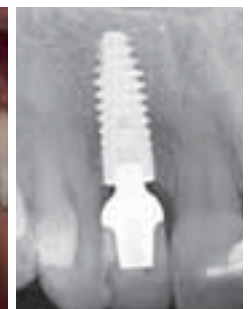
21_



22_



23_



24_