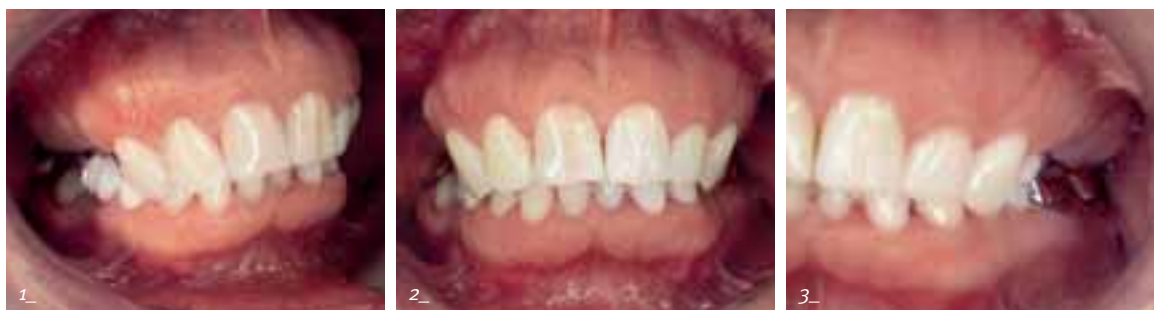



mission possible

Comprehensive restoration with Xive implants, open sinus lift and newly adjusted occlusal plane

| Hans-W. Schellekens



For many years conventional removable prostheses anchored to the teeth were the only option for compensating for partial tooth loss. Today the situation is different with the increasing use of implants, but the number of conventional dentures is still very high. But how many of the patients with such restorations have been or are really happy with them? How high might the proportion of patients be who, for a wide range of reasons, wear this type of denture reluctantly or even not at all? No one can say exactly. Patients with this problem – technically described as prosthesis intolerance – want and need help because the clinical situation can become more and more difficult to treat over the years. The earlier the problem of intolerance to a prosthesis is detected, the causes are found and a response is implemented, the easier it is to treat the resulting problems.

CASE REPORT

ANAMNESIS

After an information session at our dental practice on the topic of “bone remodeling and implant placement with unfavorable jaw conditions”, the 50-year-old patient presented for a consultation. Her case history showed that for about eight years she had not worn the upper denture because she could no longer tolerate it. The patient wanted a fixed restoration. According to her information various dentists had unfortunately rejected her desired solution because of the inadequate bone volume and all advised against an implant-supported restoration. She was finally given an interim restoration fixed with wire clamps to raise the bite. The result was an anterior open bite 3 mm high. She wore this restoration without complaint for a full year. The clinical images (Fig. 1 to 3) and the master casts (Fig. 4 and 5) clearly illustrate the situation.

PLANNING

From the first session it was clear that it would not be easy to improve the patient's situation. I really wanted to fulfill her dearest wish of having a fixed restoration. She also wanted to improve the appearance of the upper anterior teeth. After thorough analysis of the clinical diagnostic results, x-ray images and master casts, I considered various courses of action.

After discussion with the patient, the selected solution was an implant-supported denture for the upper posterior tooth region preceded by bite raising. This would urgently require augmentation in the maxilla (Fig. 6). The patient also agreed to this procedure – a bilateral open sinus lift was planned.

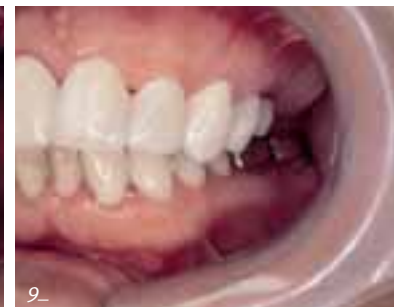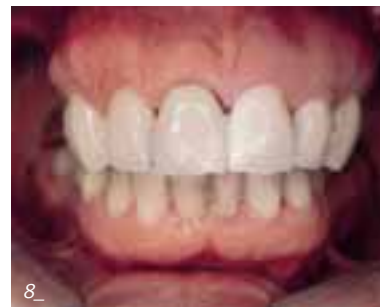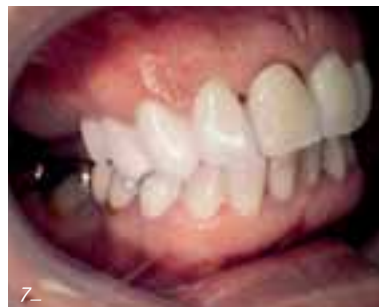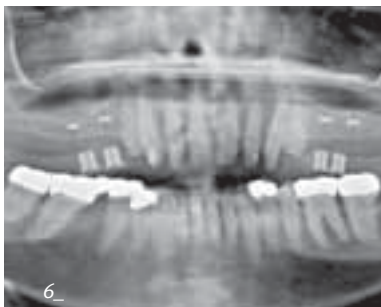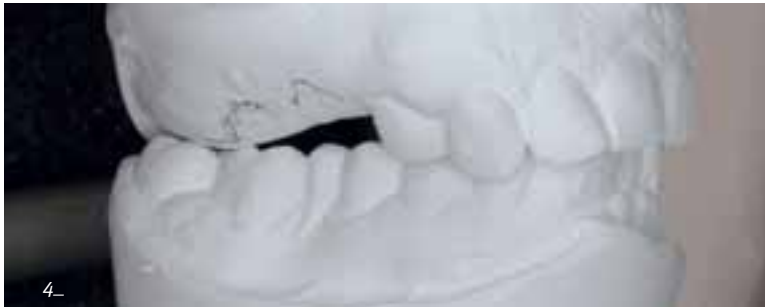During the subsequent course of treatment two Xive implants were to be placed in region 15-17 and 25-27. In the final stage it was necessary to renew the existing restorations in the mandible at the same time as the fixed denture for the maxilla was fabricated because of the change in the occlusal plane.

THERAPY

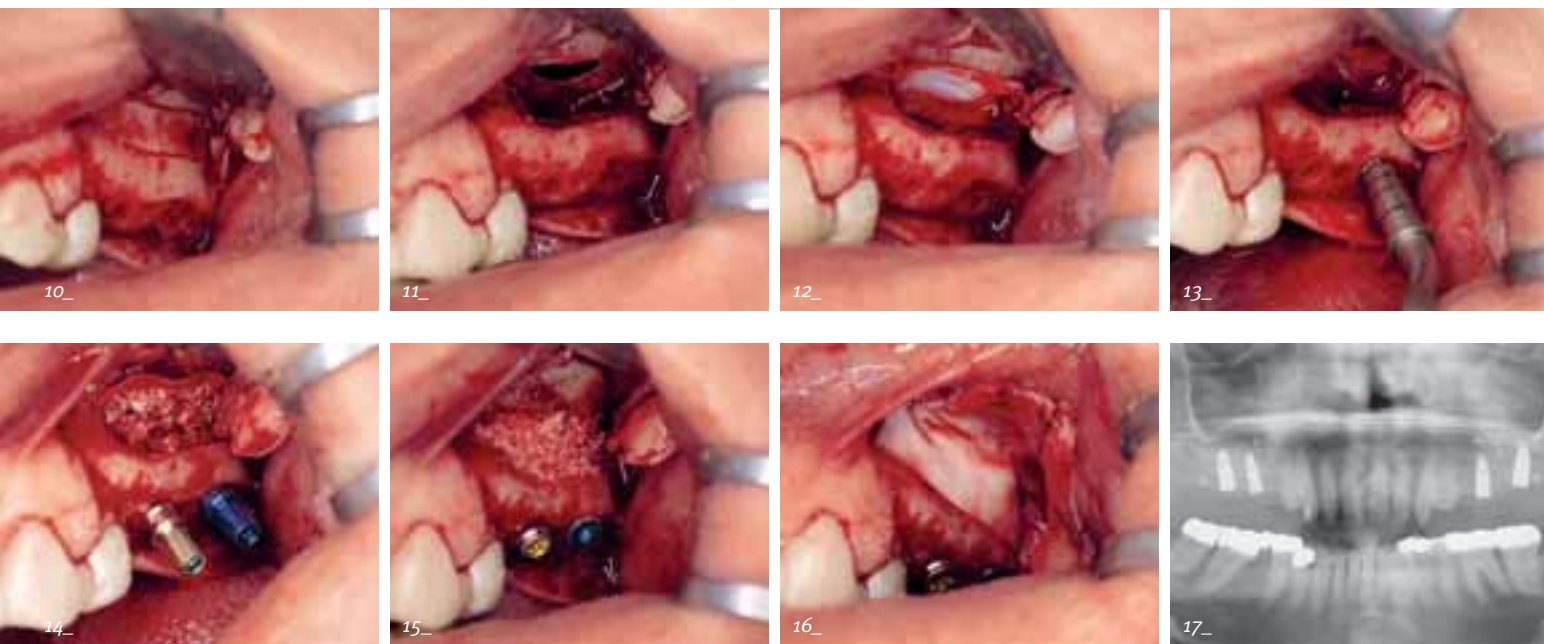
The comprehensive restoration was started with bite raising. In the first step all teeth in the maxilla were prepared. A long-term temporary denture was inserted as an interim solution with a framework of a base-metal alloy veneered with plastic (Fig. 7 to 9). The bite raising procedure required replacement of the second premolars by an extension of the crown block. The main question with such measures is always whether the patient will tolerate the modified occlusal height. Fortunately there were no problems with the patient remaining completely pain-free even after several weeks.

AUGMENTATION

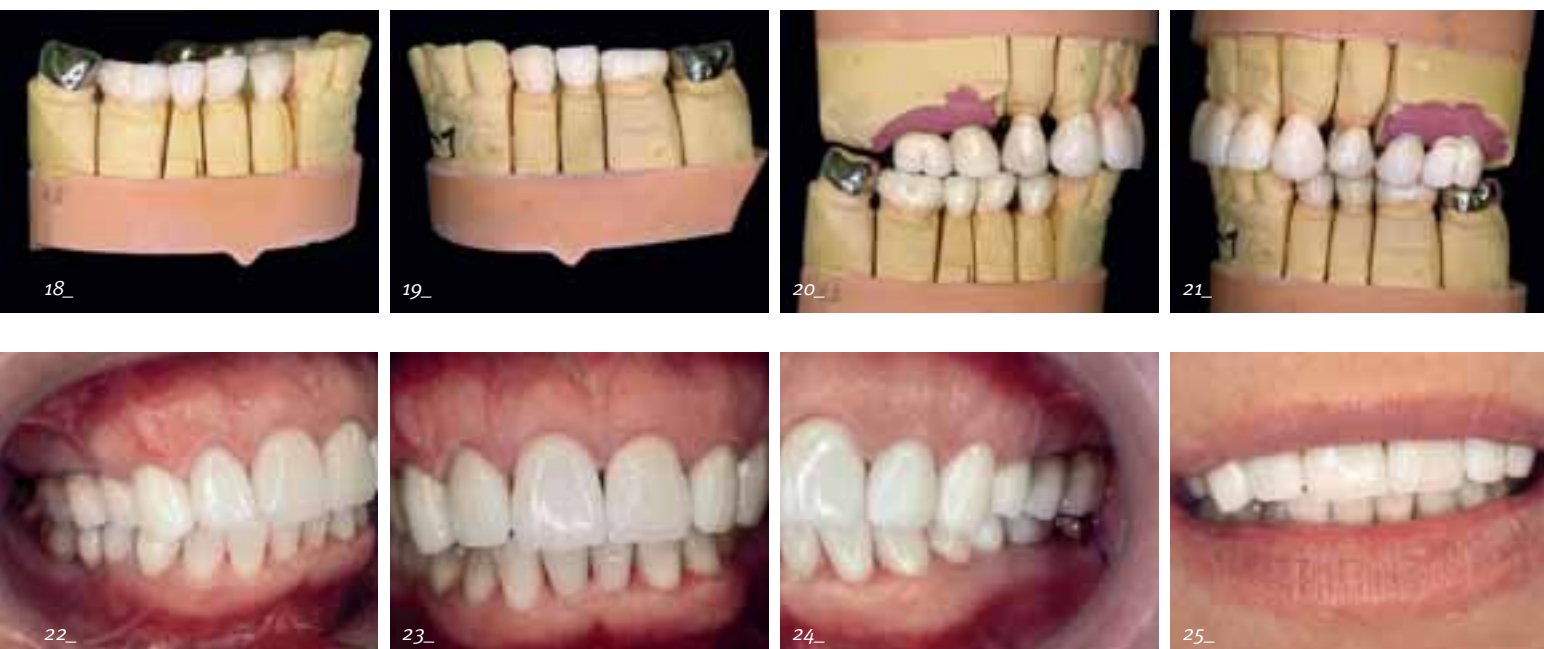
The surgical procedure turned out to be extremely difficult. The bony lid for access to the maxillary sinus was prepared with piezo technology (Fig. 10). In spite of this minimally invasive procedure, the sinus endothelium on the left side was



1, 2, 3_The 50-year-old patient was unable to wear her removable prosthesis for eight years. The lack of support resulted in reduction of the occlusal height.
 4, 5_The difficulty involved in a prosthetic restoration was clearly shown in the master cast.
 6_The maxilla was atrophied and in the region of the planned implants the bone volume was only between 5.5 mm and 8.9 mm.
 7, 8, 9_A long-term temporary denture was used to raise the bite and adjust the occlusion.



- 10_ The bony lid was prepared with piezo surgery.
 11_ In spite of minimally invasive preparation technique the sinus endothelium was ruptured.
 12_ The rupture was covered with a membrane.
 13_ The implant site was prepared by condensing the bone.
 14_ The inserted Xive implants (length 11 mm)
 15, 16_ The filled bone defect was covered by a membrane, which was fixed with Frios tacks.
 17_ The result after nine months of submerged healing
 18, 19_ The change in the occlusal height and occlusion also required a new restoration in the mandible.
 20, 21_ The finished denture before delivery
 22, 23, 24, 25_ The patient was very satisfied with the appearance and function of the fixed denture.



ruptured at the top margin (Fig. 11) because of its virtually spider-web-like consistency. The defect was covered with a membrane (Fig. 12) to prevent the augmentation material from migrating into the sinus.

After pilot drilling, the implant site was prepared by bone condensing exclusively because of the poor bone quality (D IV) (Fig. 13). Two 11 mm long Xive S implants diameter 3.8 mm and 4.5 mm were placed (Fig. 14). Because of the condensing thread design and the hydrophilic Friadent plus surface, which promotes cell growth, we expected good osseointegration even under these unfavorable conditions.

I used standard bovine bone substitution material and bone chips from the patient for the augmentation (Fig. 15). The sinus access was closed with a membrane (Fig. 16) fixed with Frios tacks (Fig. 17). The preparation of the sinus on the right side was the exact mirror image of the left side with the same type of weak bone and the extremely thin sinus endothelium. An extensive rupture also occurred here and was repaired as described above.

The postoperative period proceeded without findings in spite of the surgical complications. As a precaution we scheduled the healing period of the implants at nine months because of the weak bone conditions. The OPG (Fig. 17) taken at the end of this period showed what was expected: well osseointegrated implants. The clinical diagnosis after uncovering and the periosteal confirmed this.

PROSTHETICS

In the prosthetic phase, the old restorations in the mandible were removed. The change in the occlusal height and the occlusion required restoration of the complete mandibular posterior region (Fig. 18 and 19). The standard procedures in our practice were followed for the impression, registration, manufacture and try-in of the new restoration (Fig. 20 and 21). The shades of the anterior teeth in the maxilla were designed by the dental laboratory (Greven Zahnästhetik, Kaarst). The restoration was initially provisionally cemented-in for a few months to allow any required corrections. The patient was very pleased with the result (Fig. 22 to 25) and was completely pain-free. She accepted the modified occlusal height without difficulty. Therefore the new restoration was then cemented-in.

CONCLUSION

Unfortunately, current options for augmentation and implant placement are still not common enough in many practices – regardless of whether the procedures are carried out in the practice or patients are referred to specialists. We experience this constantly. Patients' information requirements are very high. This case report clearly shows that very good restorations are possible with augmentation and simultaneous implantation with a suitable implant system in spite of an unfavorable initial situation. Similar functional and psychological results with patient satisfaction and comfort are not possible with conventional prosthetics. ■



Dr Hans-W. Schellekens

ZTS Implantologie

Op de Fleet 7a

41189 Mönchengladbach /Germany

Phone +49 2166 58983

dr.schellekens@t-online.de

www.dr-schellekens.de



I would like to thank Gottfried Greven, MDT, who supported this procedure with great commitment.